

Internal Mammary Retractor

Rais A. Beg, M.D., H. Naraghypour, M.D., Earle B. Kay, M.D., and Phil Rullo, Chief Perfusionist

ABSTRACT: A retractor for dissection of the internal mammary artery, the instrument can be easily applied to the chest wall providing excellent exposure for dissection of the graft from origin to bifurcation.

The retractor has been in use for nearly twenty years, in over 6000 cases. It gives powerful but easily controllable mechanical lift in a relatively atraumatic manner.

Sterilization Process

Gas Sterilization

Steam sterilization unwrapped 3 minutes.

Steam sterilization wrapped ½ hour.

Retractor can be sterilized as one unit to expedite setup of instrument in surgery.

Note — Instrument does not have to be disassembled after each use. Cleaning procedures are according to your institution.




Fig. 2
Sterile technique - table clamp.
Clamp over sterile drape.

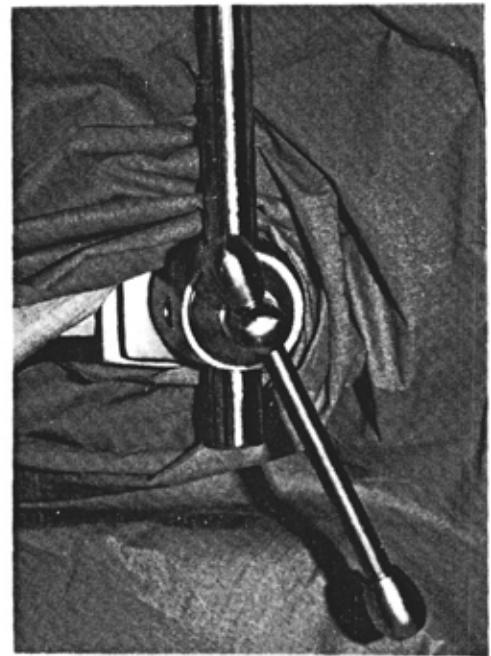


Fig. 1
Non sterile technique -
Stirrup holder provided with your table.

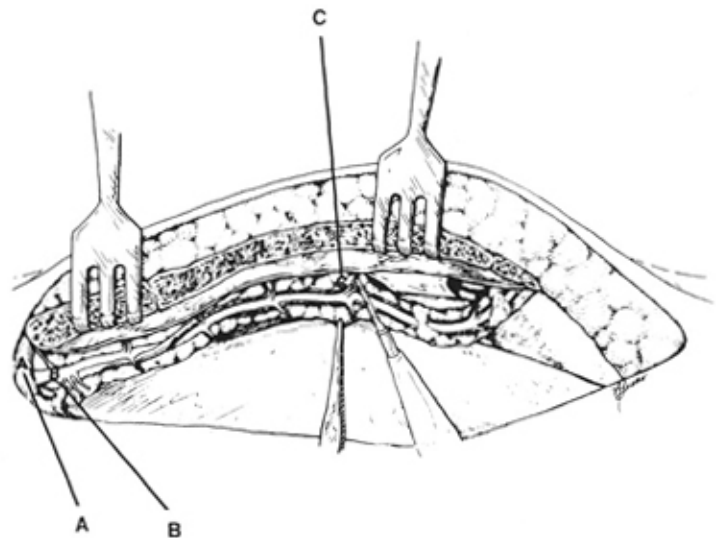


Fig. 3
Proper placement of rakes at lower manubrium and lower sternum. Parallel incisions 1cm lateral and medial to the internal thoracic vessels. Gentle traction from the lateral edge of the pedicle helps in the dissection. (A) Subclavian vein. (B) Internal thoracic artery. (C) Perforating branches.

Internal Mammary Retractor

Rais A. Beg, M.D., H. Naraghipour, M.D., Earle B. Kay, M.D., and Phil Rullo

ABSTRACT. A new retractor for dissection of internal mammary arteries is described. We have found that the instrument can easily be applied to the chest wall and gives excellent exposure for dissection of the graft from origin to bifurcation.

Use of the internal mammary artery as a conduit for aortocoronary bypass has attracted increasing interest (1-5). The artery's high-velocity flow, long-term patency, and immunity to long-term failure make it an ideal vessel for this purpose.

Success of the mammary graft depends on proper harvesting of the artery from the chest wall, as well as judicious handling and anastomosis of the vessel. In our experience of more than 5,000 internal mammary artery grafting procedures over the last 14 years, the most common cause of poor flow through the mammary graft at the time of operation was formation of a hematoma in the pedicle or a cautery burn, which resulted in narrowing; however, very rarely did atheroma formation or small size of the mammary artery render it unusable. We have devised a retractor for internal mammary artery dissection (Fig 1)* that helps prevent these problems and facilitates performance of the grafting procedure.

Technique

After the midsternotomy incision is made, the retractor is applied to the sternal edge (Fig 2), which

allows the chest wall to be retracted upward and outward, and exposes the entire course of the mammary artery from its origin to its bifurcation. The vessel can then be dissected (Fig 3).

Comment

We have used the retractor for more than 20 years in internal mammary artery grafting procedures. The instrument provides good exposure and allows the surgeon sufficient access for dissection.

References

1. Szilágyi DE, Elliott JP, Hageman JH, et al: Biologic fate of autogenous vein implants as arterial substitutes: clinical, angiographic and histopathologic observations in femoropopliteal operations for atherosclerosis. *Ann Surg* 178:232, 1973.
2. Grondin CM, Campeau L, Lespérance J, et al: Atherosclerotic changes in coronary artery grafts six years after operation: angiographic aspect in 110 patients. *J. Thorac Cardiovasc Surg* 77:24, 1979.
3. Lytle BW, Loop FD, Cosgrove DM, et al: Long-term (5-12 year) sequential studies of internal mammary artery and saphenous vein coronary bypass grafts. *Circulation* 68:Suppl 3:114, 1983.
4. Okies JE, Page US, Bigelow JC, et al: The left internal mammary artery: the graft of choice at Good Samaritan Hospital and Medical Center, Portland, OR. *Circulation* 68:Suppl 3:21, 1983.
5. Kay EB, Naraghipour H, Beg RA, et al: Internal mammary artery bypass graft—long-term patency rate and follow-up. *Ann Thorac Surg* 18:269, 1974.




Fig 1. Retractor.

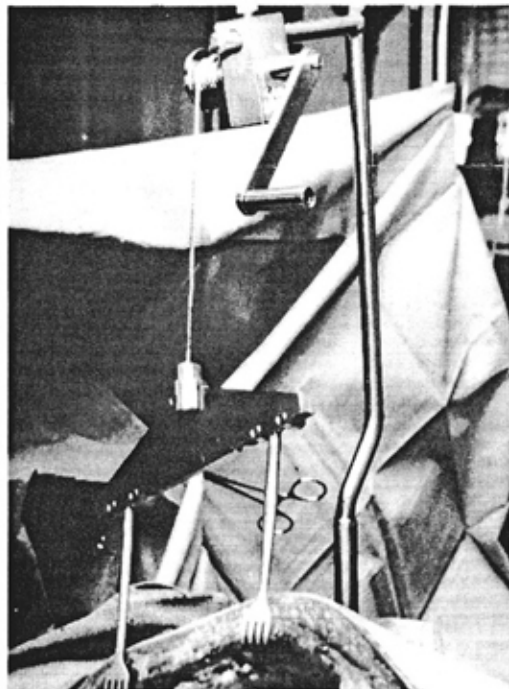


Fig 2. Retractor applied to left chest wall with upward and outward retraction.

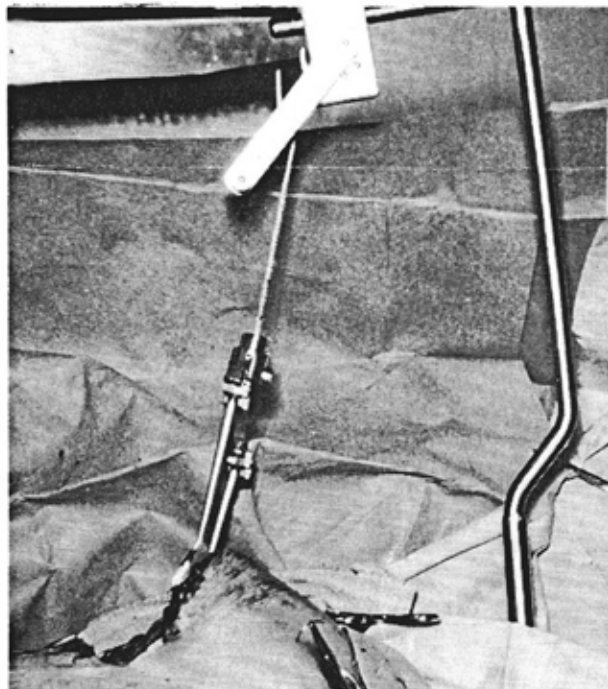


Fig 3. Internal mammary artery dissected and lifted upward from its origin.